



Dr Claire Pritchard ST3 GUM

Dr Fath Alloba Associate Specialist

Axess Centre, Royal Liverpool University  
Hospital

# Syphilitic balanitis...is it an atypical presentation of Syphilis?

# Aim

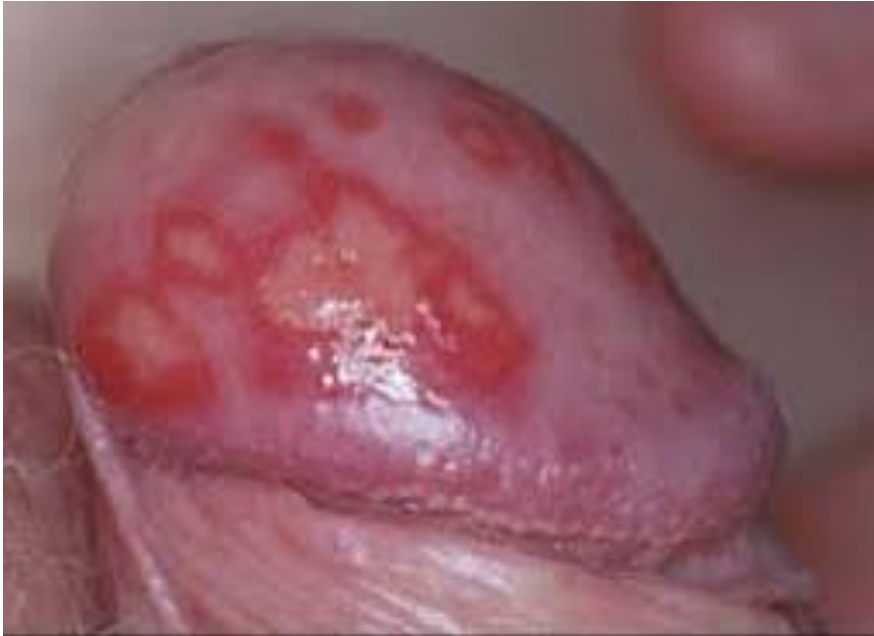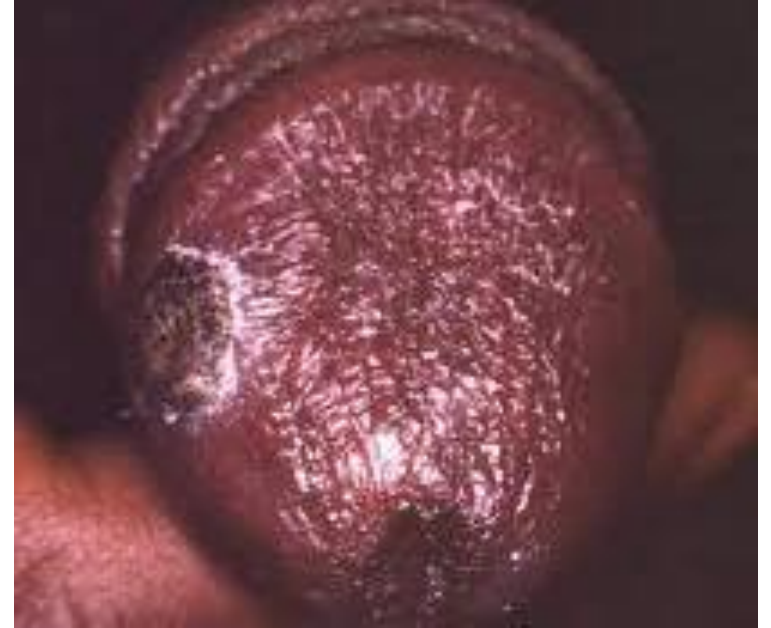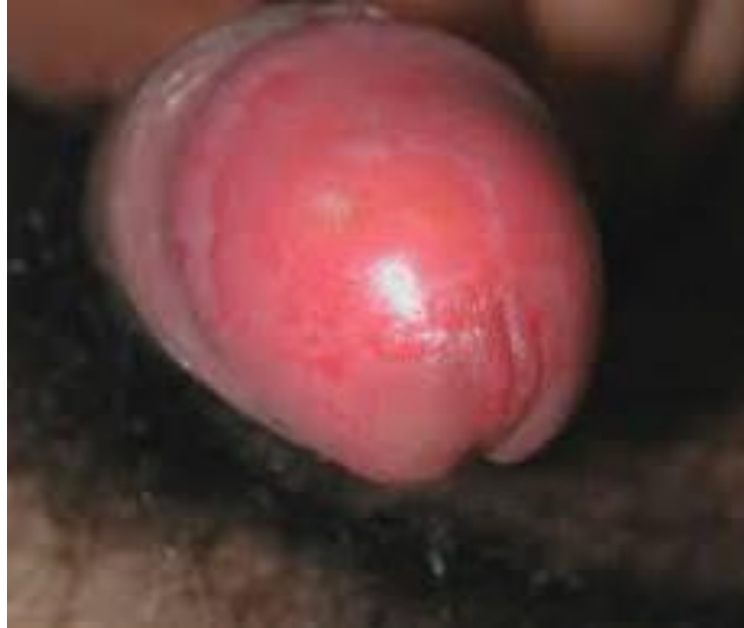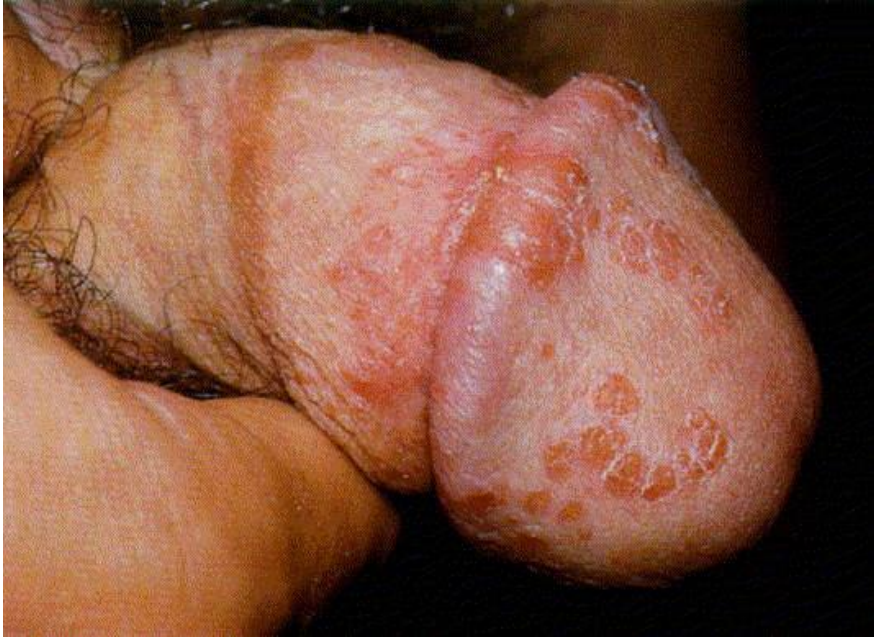To investigate the hypothesis that a number of cases of balanitis seen in our clinic were related to Syphilis

# Background

First described by Dr Eugene Follman in 1948

0.3-0.5% of cases of Syphilis<sup>1</sup>

Erosive balanitis with associated inguinal lymphadenopathy



Balanitis of Follman

---

# Methods

---

Retrospective review of case notes for males coded as A1, A2 or A3 who attended in 2017

---

Literature search for case reports performed

---

123 references were reviewed based on search strategy using Embase, CINAHL and PubMed

## Results

25/112 (22%) of patients had balanitis

7 treated for fungal balanitis

7 treated for HSV

1 treated for anaerobic balanitis

92% had RPR >1:32

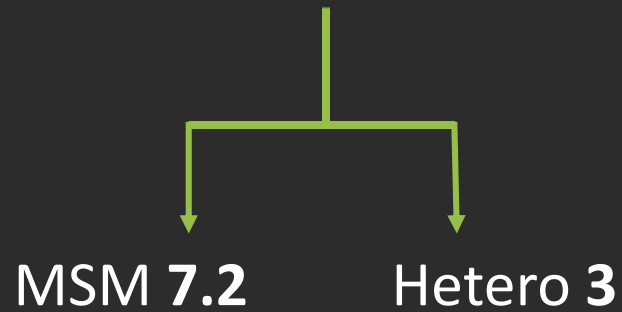
67% with A1 and 32% with A2

Resolution of balanitis with Benzathine

# Demographics

- 21/25 MSM
- 4 patients living with HIV
- 5/25 had had Syphilis in the past
- 19/25 had had a previous STI

Mean no. of partners in 1 year



# Discussion



Balanitis is a symptom of early syphilis



Delays in diagnosis contribute to onward transmission



Balanitis is a feature of primary and secondary syphilis



Dark ground negative in several case reports



TPPCR helpful in diagnosis



Thank you

Dr Fath Alloba  
Library team at RLUH

# References

1. Imrie, M. Oanta, A. 2014, Syphilitic Balanitis of Follman, *International Journal of Dermatology*, 53, 830-831
2. Mainetti, C. Scolari, F. Lautenschlager, S. 2016, The Clinical Spectrum of Syphilitic Balanitis of Follman: a report of five cases and a review of the literature, *European Journal of Dermatology and Venereology*, 30, 1810-1813